



## Virtual Slide Congress. Case # 07

- Slides Index

- Home

A Forteza\*, Alexandra Gené\*, R Ramos\*, F Terrasa\*, M Company\*, Ramón Canet\*  
 \* Hospital Universitario Son Dureta. Palma de Mallorca ESPAÑA

- Top

- Virtual Slide
- Case Report
- DIAGNOSIS
- Pathology
- References

### Case Report

A female fetus, stillborn at 27 weeks' gestation, who presented a generalized subcutaneous edema without other malformations.

#### MACROSCOPIC FINDINGS

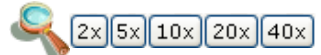
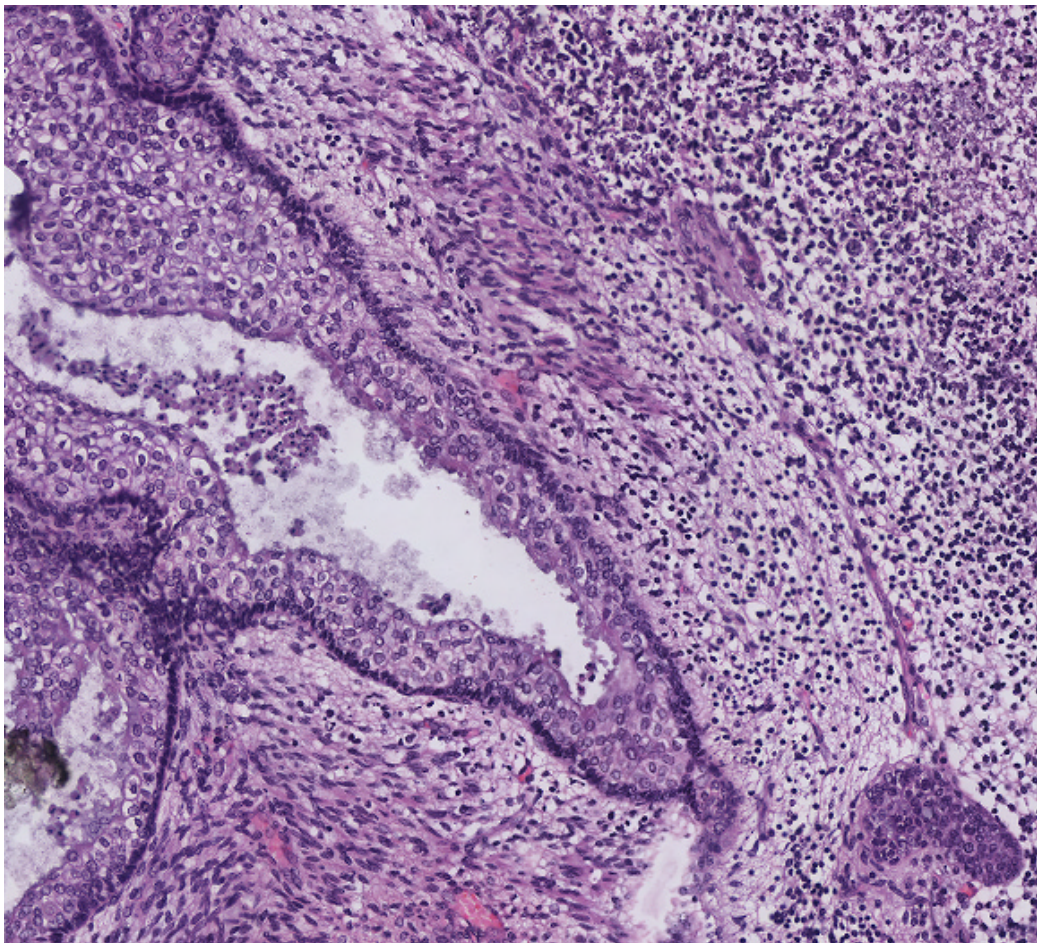
In the macroscopic exam we found in the thoracic cavity a pleural effusion and a big growing expansive mediastinal neoplasm that measured 8 cm and weighted 56 g. The cut surface showed fleshy appearance and some cystic areas. The lungs were small, weighted 10 g but had a correct lobulation.



WebMicroscope

This slide's been kindly digitized by [WebMicroscope's team \(Finland\)](#)  
 Preparación amablemente digitalizada por los responsables de [WebMicroscope \(Finlandia\)](#)

### H&E Lung



Contrast: 1.00

Brightness: 1.00

Case 7, C7 - 1 (x40)

Regions of Interest: [On/Off](#)

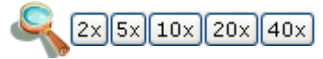
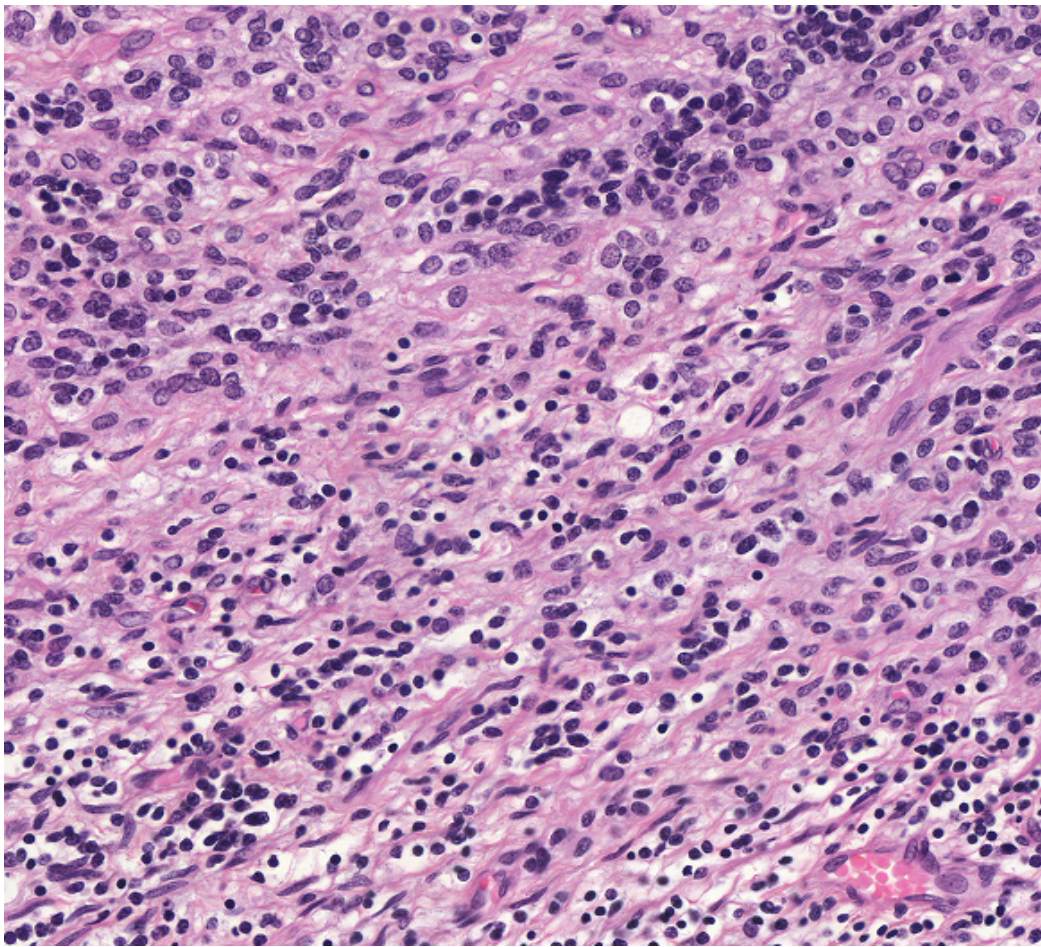


[See virtual slide in full window size - Ver caso en Webmicroscope](#)



WebMicroscope

This slide's been kindly digitized by [WebMicroscope's team \(Finland\)](#)  
Preparación amablemente digitalizada por los responsables de [WebMicroscope \(Finlandia\)](#)  
**H&E Lung**



Contrast: 1.00

Brightness: 1.00

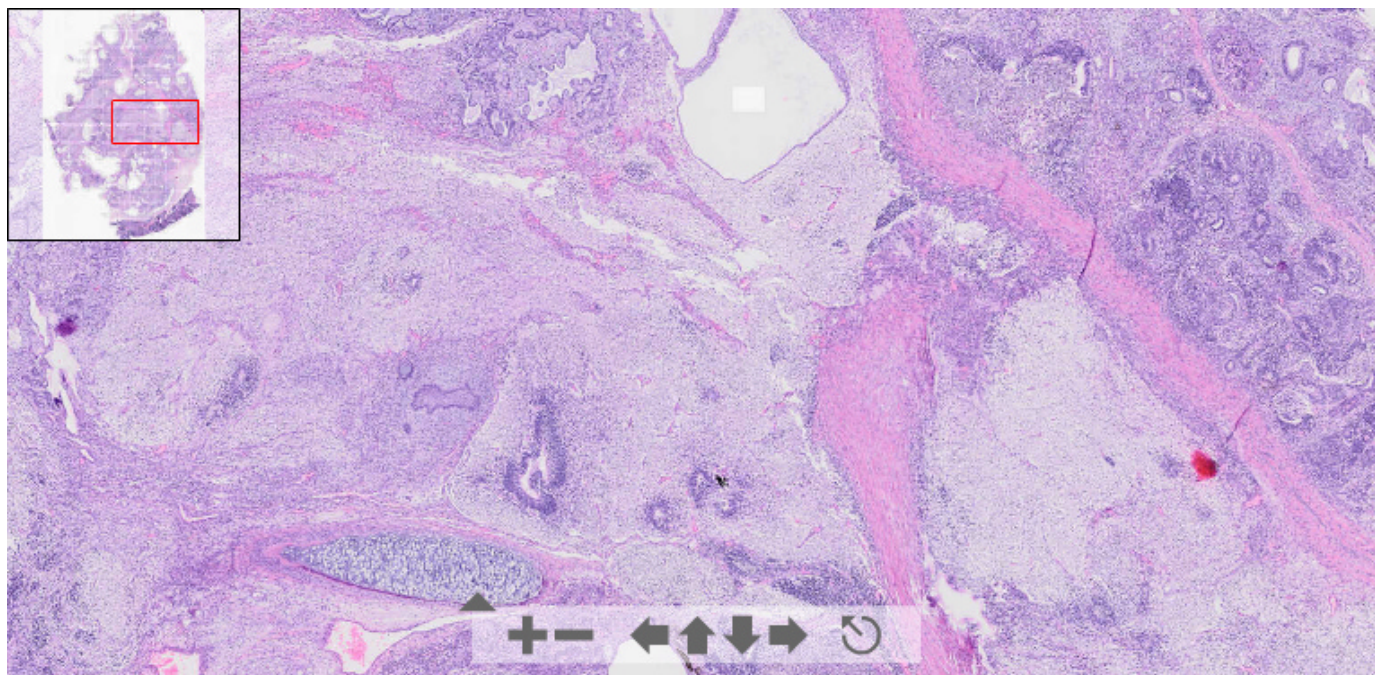
Case 7, C7 -2 (x20)  
Regions of Interest: [On/Off](#)



[See virtual slide in full window size - Ver caso en Webmicroscope](#)



This slide's been digitized with [Olympus/SIS dotslide system](#)  
Preparación digitalizada con el sistema [Olympus/SIS dotslide](#)  
**H&E Lung. Same as slide 1, digitized with other system**



(See virtual slide in full window size- Ver preparación en ventana completa)

- Top
- Virtual Slide
- Case Report
- DIAGNOSIS
- Pathology
- References

**Diagnosis**

- Congenital cystic adenomatoid malformation of lung (Malformación adenomatoide quística congénica del pulmón)
- Chondrodysplasia (Condrodisplasia)
- Right-sided diaphragmatic hernia (Hernia diafragmática derecha)
- Pulmonary sequestration (Secuestro pulmonar)
- Other intrathoracic mass/tumor

**FINAL DIAGNOSIS IS BELOW THIS LINE**

- Top
- Virtual Slide
- Case Report
- DIAGNOSIS
- Pathology
- References

**DIAGNOSIS**

ANTERIOR MEDIASTINAL IMMATURE TERATOMA

- Top
- Virtual Slide
- Case Report
- DIAGNOSIS
- Pathology
- References

**Pathology**

MICROSCOPIC FINDINGS

The mediastinal neoplasm was composed of immature and mature tissues representing each of the three layers derived from the embryonic disk. We found dermal structures and neural, gastrointestinal, bronchial, muscular and fatty tissues with some cystic lesions. We observed some immature neuroectodermic areas with neuroepithelial cells forming tubules and rosettes. Surrounding the neoplasm atrophic thymic rests could be found.

**DIAGNOSIS:**

1. HYDROPS FETALIS.
2. ANTERIOR MEDIASTINAL IMMATURE TERATOMA

3. BILATERAL PULMONARY HYPOPLASIA CAUSED BY INTRATHORACIC COMPRESSION

Figura 1

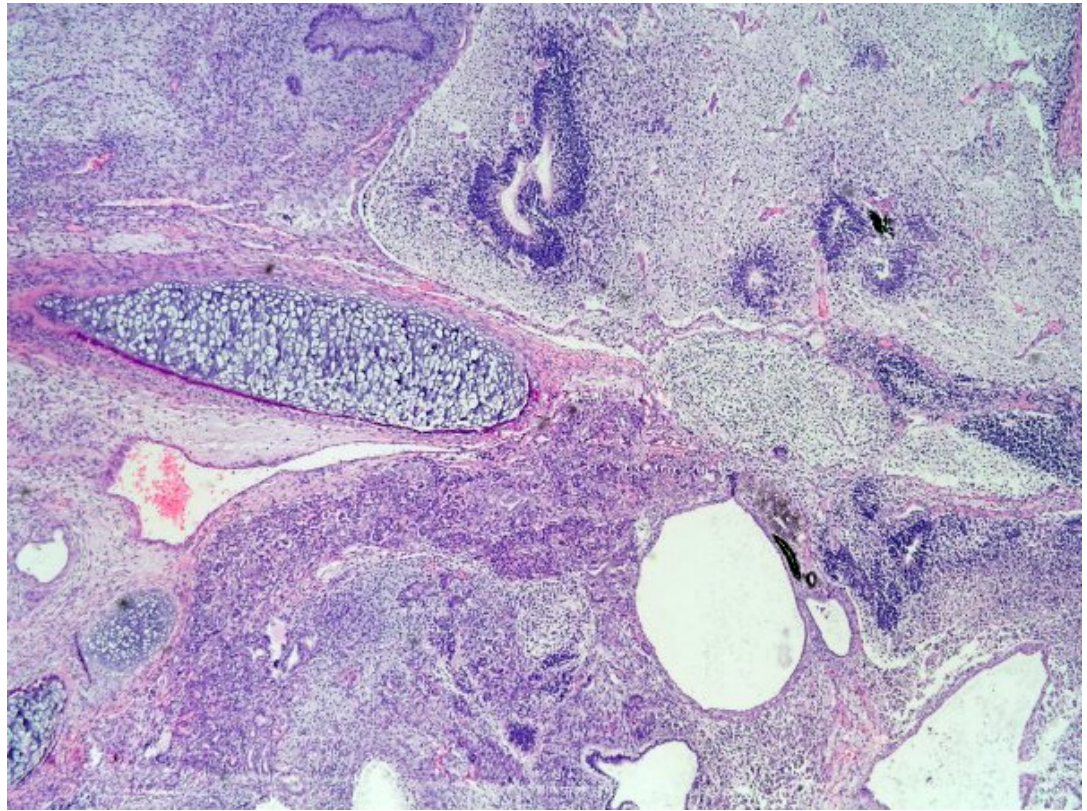
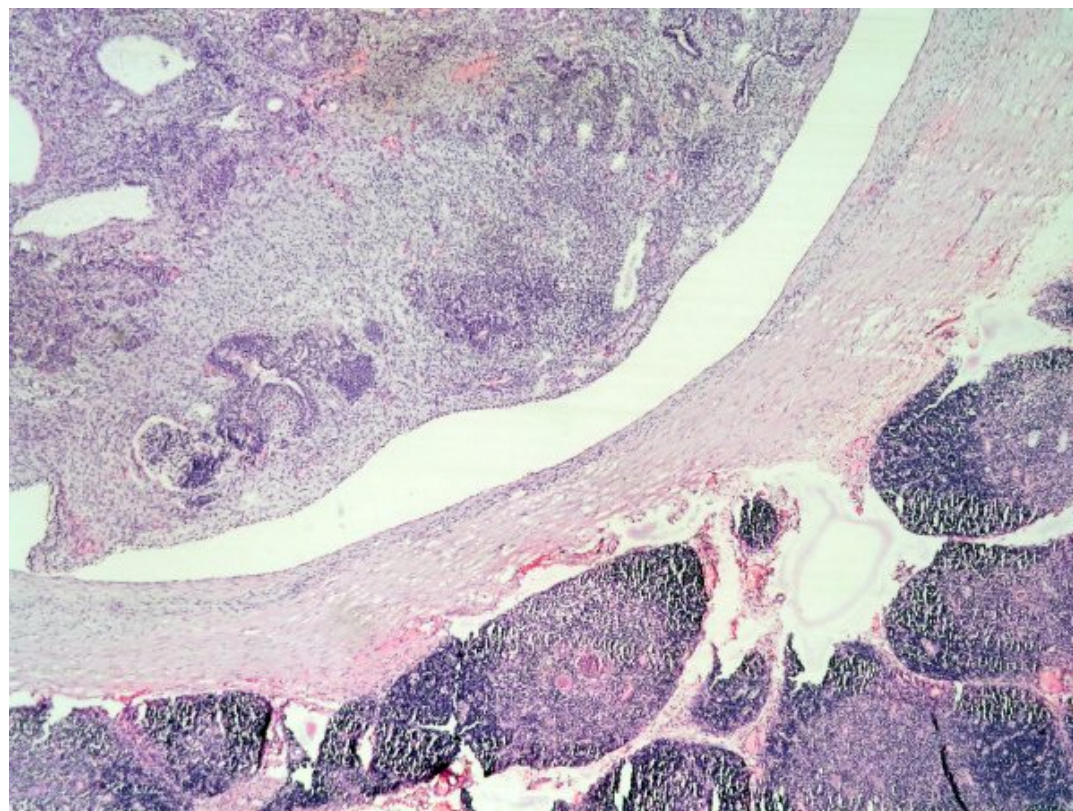


Figura 2



- Top
- Virtual Slide
- Case Report
- DIAGNOSIS
- Pathology
- References

## References

- 1 - Froberg MK, Brown RE, Maylock J, Poling E. In utero development of a mediastinal teratoma: a second-trimester event. *Prenat Diagn.* 1994 Sep;14(9):884-7.
- 2 - Weinraub Z, Gembruch U, Fodisch HJ, Hansmann M. Intrauterine mediastinal teratoma associated with non-immune hydrops fetalis. *Prenat Diagn.* 1989 May;9(5):369-72.

- Top
- Virtual Slide
- Case Report
- DIAGNOSIS
- Pathology
- References

## Comments

### - Bernardo Weil Lara (11/10/2005 18:08:15)

Immature congenital teratoma. Were there any area of endodermal sinus tumour?  
*Teratoma congénito inmaduro. Ha observado focos de tumor del seno endodérmico?*

### - Mirta Garcia Jardon (27/10/2005 8:11:02)

In one case of the congress about a mediastinal mass I made a comment about extragonadal localization of germ cell tumours, and this is a good example. Pictures are excellent, mainly in the area including thymus.

*Hice un comentario en un caso del congreso con una masa mediastinal acerca de la localización extragonadal de los tumores de células germinales, y este es un buen ejemplo. Las fotos son magnificas, sobre todo la que incluye parte del timo.*

### - Cesáreo Corbacho Cuevas (03/11/2005 20:58:03)

It is a very interesting case with splendid images. Thanks a lot and warmest regards.  
*Un caso muy interesante con unas imagenes esplendidas. Muchas gracias y un saludo muy cordial.*

### - Maribel DONASTORG (10/11/2005 13:22:13)

Muy interesante caso, una imagenes histologicas magnificas.

Maribel Donastorg

---

---

Web mantenido y actualizado por el [Servicio de informática](#). Modificado: 31/01/2006 2:23:53