



Virtual Slide Congress. Case # 03

- Slides Index

- Home

Alexandra Gené*, J Reyes*, A Forteza*, M Company*, J Torralba*, M Couce*, Ramón Canet*
* Hospital Universitario Son Dureta. Palma de Mallorca ESPAÑA

- Top

- Virtual Slide
- Case Report
- **DIAGNOSIS**
- Pathology
- References

Case Report

A 64 year old patient who presented with diarrhea, abdominal pain, asthenia, 8-10 kg weight loss and progressive food intolerance that required parenteral nutrition. In addition, he had been treated for unknown-germ pneumonia three weeks earlier.

Abdominal CT-scan showed small bowel handles distention without obstruction signs.

Stool examination was negative.

Gastroscopy showed an absence of Kerkring folds and abnormal villi pattern in the second duodenal portion. Biopsies were taken.

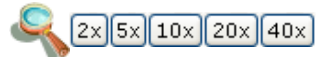
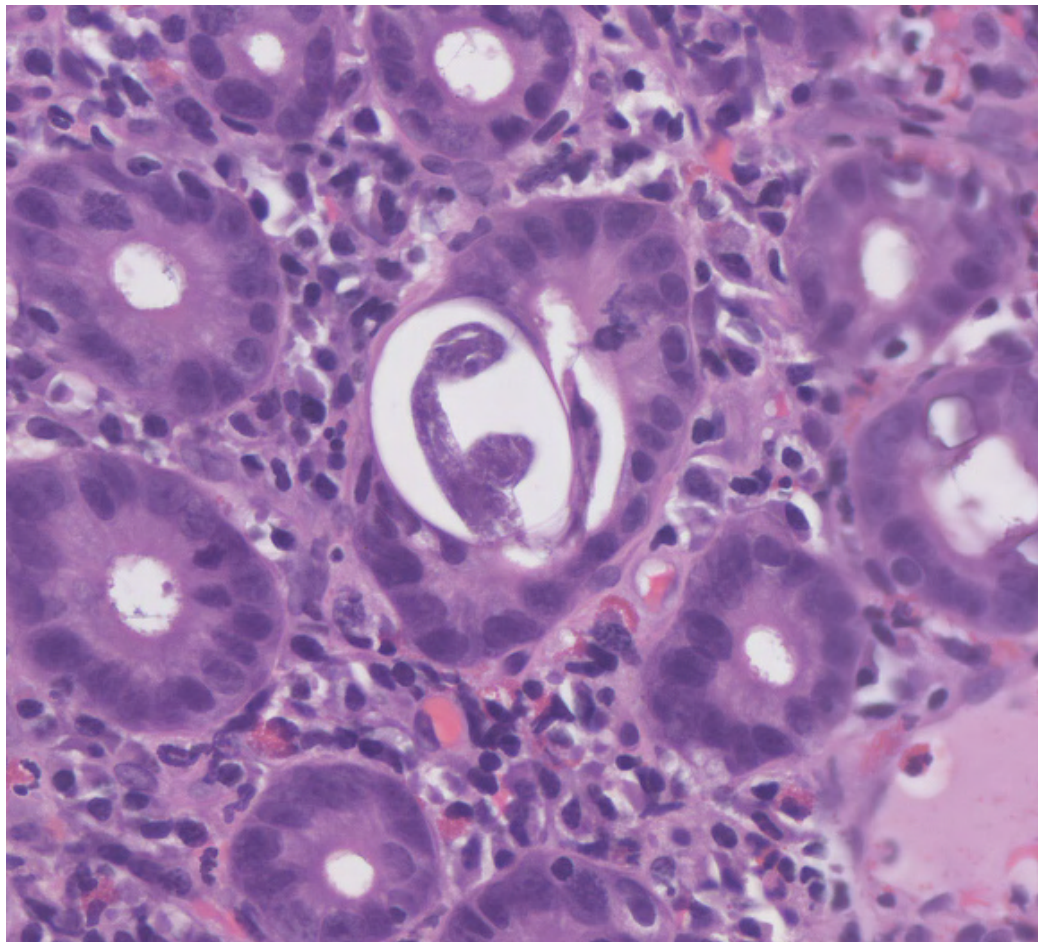


WebMicroscope

This slide's been kindly digitized by [WebMicroscope's team \(Finland\)](#)

Preparación amablemente digitalizada por los responsables de [WebMicroscope \(Finlandia\)](#)

H&E



Contrast: 1.00

Brightness: 1.00

Case 3, C3 (x40)

Regions of Interest: [On/Off](#)



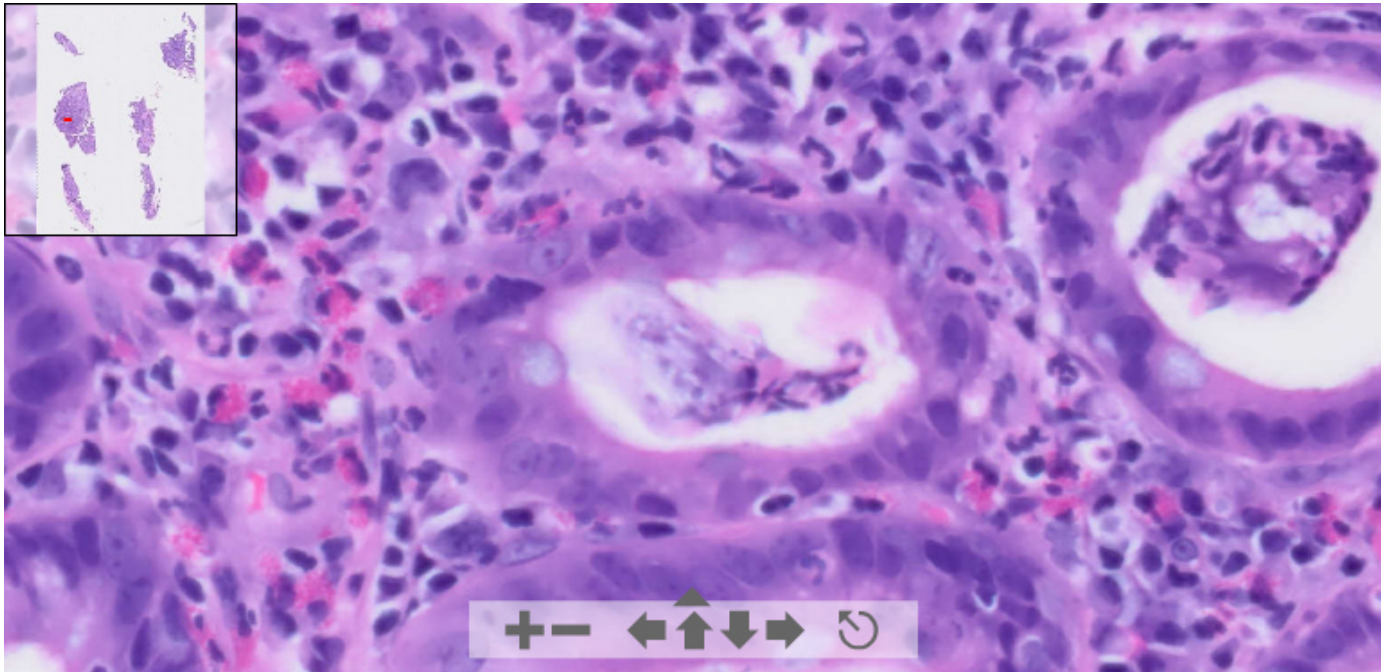
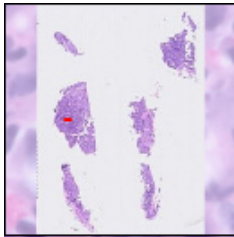
See virtual slide in full window size - Ver caso en Webmicroscope

OLYMPUS

Your Vision, Our Future

This slide's been digitized with **Olympus/SIS dotslide system**
Preparación digitalizada con el sistema **Olympus/SIS dotslide**

H&E. Same slide, digitized with a different system



(See virtual slide in full window size- Ver preparación en ventana completa)

- Top
- Virtual Slide
- Case Report
- DIAGNOSIS
- Pathology
- References

Diagnosis

- Celiac disease (Celiaquía)
- Whipple´s disease (Enfermedad de Whipple)
- Parasitic infestation (Parasitosis)
- Intestinal lymphangiectasia (Linfangiectasia intestinal)
- Tropical sprue

FINAL DIAGNOSIS IS BELOW THIS LINE

- Top
- Virtual Slide
- Case Report
- DIAGNOSIS
- Pathology
- References

DIAGNOSIS

INTESTINAL STRONGYLOIDIASIS

- Top
- Virtual Slide
- Case Report
- DIAGNOSIS

Pathology

Pathologic findings:

We received eight duodenal samples that measured between 0,2 and 0,4 mm. Histologically we found several adult

- Pathology
- References

female worms lying within the small bowel's crypts. A typical transverse section through the posterior region of the worm contains an intestine and two sections of the reproductive tube. The lamina propria contains numerous plasma cells, eosinophils and neutrophils. All these findings are compatible with *Strongyloides stercoralis* infection.

Figure 1

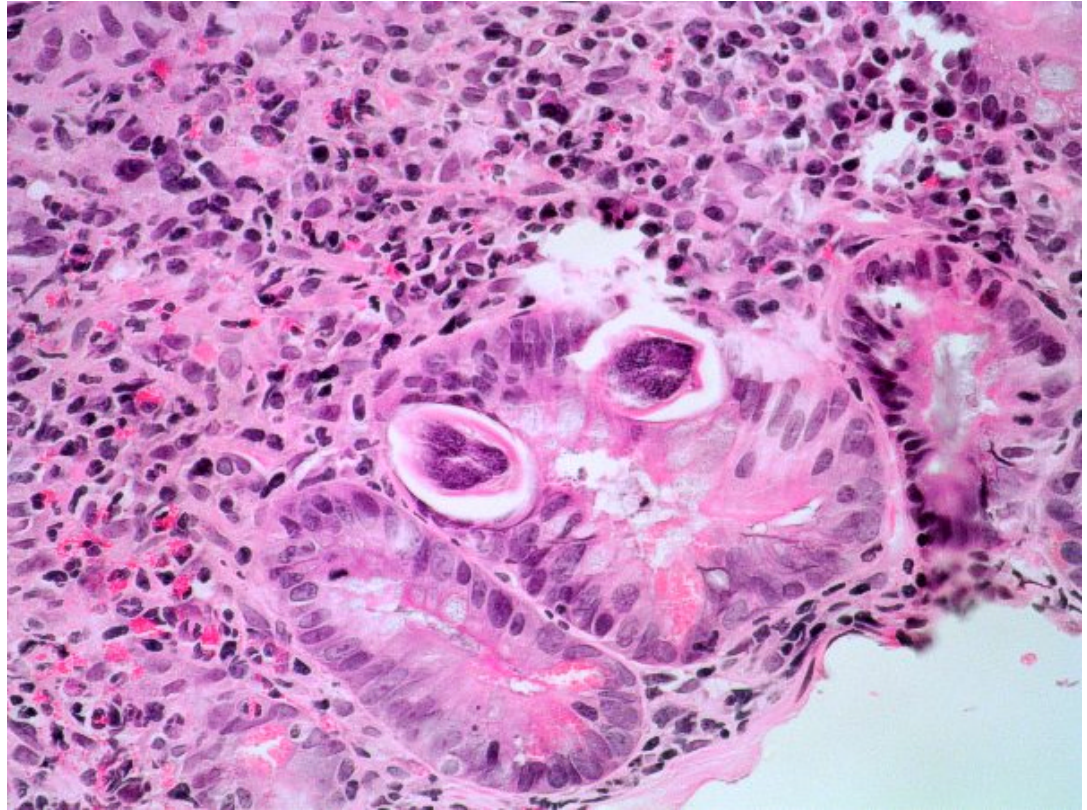


Figure 2

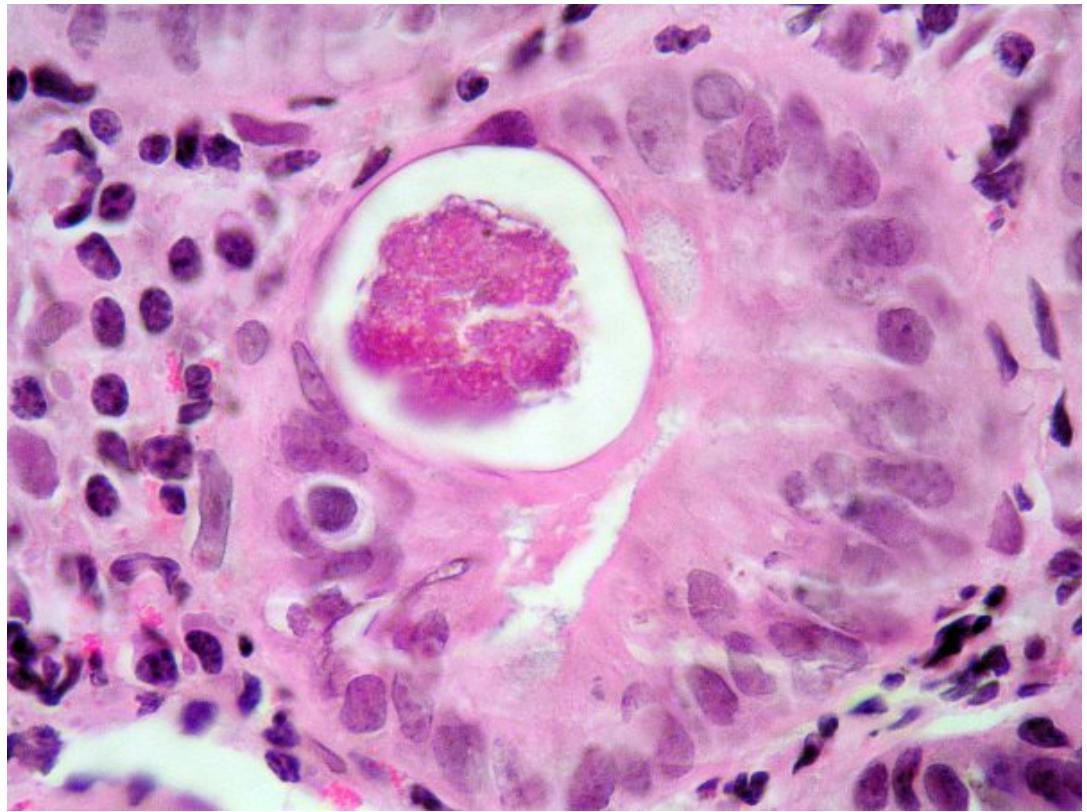
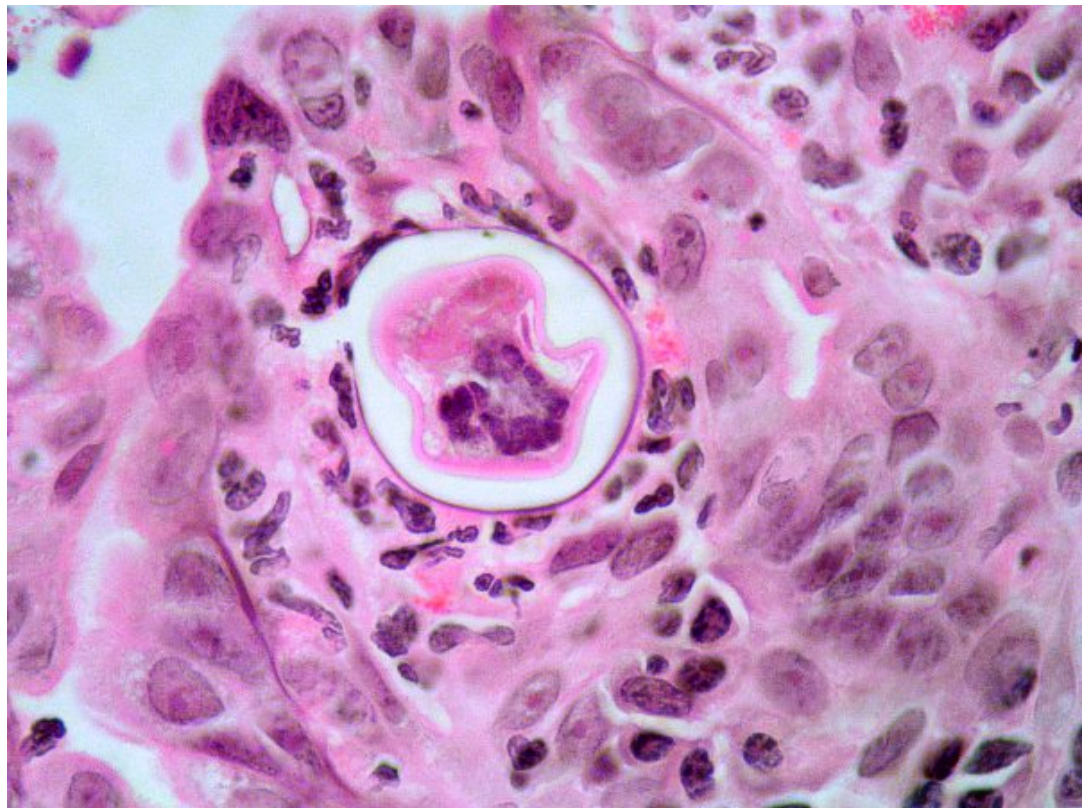


Figure 3



References

- Top
 - Virtual Slide
 - Case Report
 - DIAGNOSIS
 - Pathology
 - References

- 1 - Atul S, Ajay D, Ritambhara N, Harsh M, Ashish B. An unusual cause of malabsorption in an immunocompetent host. J Ayub Med Coll Abbottabad. 2005 Jan-Mar; 17(1):85-6.
- 2 - Asano K, Tada S, Kamio T, Matsumoto T, Suko H, Iida M. Strongyloidiasis. Gastrointest Endosc. 2004 Oct; 60(4):606-7.
- 3 - Pathology of tropical and extraordinary diseases. Armed Forces Institute of Pathology.

- Top
 - Virtual Slide
 - Case Report
 - DIAGNOSIS
 - Pathology
 - References

Comments

- María Caridad De Armas Fernández (03/10/2005 17:34:39)

A very interesting case, I had a similar case of jejunal localization. Image are very representative of the parasite.

Caso muy interesante, tuve la experiencia de un caso con diagnóstico similar en el yeyuno. Imágenes muy representativas del parásito.

- HUGO GÓNGORA JARA (03/10/2005 17:37:53)

INTESTINAL PARASITOSIS:

Parasitic-type elements are observed in intestinal glands, intraluminal and other, apparently at intercellular level, deforming epithelial cells.

Personally, I did not find easy to classify the agent. Images are excellent in the virtual microscope, as well as digital images. Congratulations to Congress organisers and to the authors of the paper.

PARASITOSIS INTESTINAL:

Se observan elementos de tipo parasitario en glándulas intestinales a nivel intraluminal y otras aparentemente a nivel intracelular, deformando las células epiteliales. Personalmente no me pareció fácil tipificar el agente. Excelentes imágenes del microscopio virtual, así como de las fotografías digitales. Felicitaciones a los organizadores del Congreso y a los autores del trabajo.

Dr. Góngora Jara, Hugo. La Rioja. Argentina.

- Bárbara O. Estupiñán Díaz (03/10/2005 17:39:55)

It is a very interesting case, which I suppose has been epidemiologically studied. We thought of a parasitic infection because of the eosinophilic infiltrate and the existence of something unusual in gland lumens.

Congratulations

Caso muy interesante, imagino que se haya estudiado desde el punto de vista epidemiológico.

Pensamos en una infección parasitaria por el aumento del infiltrado eosinofílico y la presencia en la luz de la glándula de algo inusual.

Felicidades.

- Cesáreo Corbacho Cuevas (03/10/2005 18:34:35)

A very interesting case with excellent pictures. Congratulations.

Un caso muy interesante con una iconografía excelente. Enhorabuena.

- Agustín Acevedo Barberá (04/10/2005 19:01:11)

It is a very interesting case, and it can be diagnosed with conventional histology, and with the presented virtual images. Was the patient contaminated there or did he come from other area?

Caso muy bonito y que puede diagnosticarse con la histología convencional y con las imágenes virtuales ofrecidas. ¿El paciente se contaminó allí o provenía de algún otro sitio?

- Emilio Mayayo Artal (04/10/2005 23:43:05)

Congratulations for the case. Was the parasite studied?

Felicidades por el caso. ¿Se realizó estudio del parásito?

- shanthi palanivelu (05/10/2005 5:01:41)

the photomicrographs are typical and interesting.

- hector santiago antunez moncada (05/10/2005 7:51:46)

Interesting and showy. Congratulations

Interesante y llamativo. felicitaciones . Honduras CA

- Ignacio Zabalza Estevez (05/10/2005 13:22:55)

This is a beautiful case, and very uncommon in our environment. I had only seen one similar case in the seminar of paediatric pathology of the Madrid 1992 Congress.
Un caso muy bonito y que realmente en nuestro medio es muy raro. Solo había visto uno igual en el seminario de patología pediátrica del congreso de Madrid de 1992.

- **JORGE SAINZ BALLESTEROS** (06/10/2005 1:14:11)

It is a very interesting and didactic case, and the pathologist must look for corresponding elements in the slide in order to make a correct diagnosis.

Caso muy interesante, que es muy docente y que el patólogo debe buscar los elementos correspondientes en la lamina para realizar un diagnostico correcto.

DR JORGE SAINZ BALLESTEROS. CUBA

- **Esther Nahir Contreras Valerio** (07/10/2005 13:23:07)

I had the opportunity to observe a similar case of massive Strongyloidiasis in an autopsy case in Mexico. This one is very interesting and important to know. Thanks.

Tuve la oportunidad de observar un caso de Strongyloidiasis masiva en un caso de autopsia en México. Un caso muy interesante e importante de conocer. Gracias.

- **Juan antonio Suarez Gonzalez** (09/10/2005 15:49:37)

Very interesting, and, above all, very well presented. Thanks for your kindness
muy interesante, y sobre todo muy bien presentado. Gracias por la gentileza

- **Bernardo Weil Lara** (11/10/2005 17:56:13)

Beautiful
Muy bonito

- **Mirta Garcia Jardon** (27/10/2005 8:06:32)

We often have cases like this, and amebiasis too. Eosinophilia in lamina propria is a good clue.

Nosotros tenemos casos de ese tipo relativamente frecuente, y también amebiasis. La eosinofilia en la lámina propia es una buena pista.

- **MIGUEL ANGEL CARRASCO GARCIA** (27/10/2005 13:53:54)

Interesting case, especially for those of us who do not often see parasitic diseases

Caso interesante, especialmente para los que no vemos con frecuencia enfermedades parasitarias.

- **M^a J. ILDE ZAMACOLA ARISTEGUI** (31/10/2005 16:00:55)

It is a case with beautiful images. Many thanks
Caso con imágenes muy bonitas. Muchas gracias.

- **Victor Leonel Argueta Sandoval** (04/11/2005 4:13:30)

The case is specific, no other studies are needed, because of the site where it was found. Images are diagnostic.

El caso es específico, sin mayores estudios, por el lugar donde se encuentra. Imágenes diagnósticas.

- **Romualdo Lins** (04/11/2005 5:19:03)

It is a very interesting and didactic case, with beautiful images. Congratulations to the authors.

Caso muito interessante e didático, com imagens belissimas. Parabéns aos autores.
Romualdo

- **Nancy Ríos Hidalgo** (06/11/2005 3:23:06)

It is an interesting and very demonstrative case, congratulations for the slides. By the way, I had the opportunity to observe a similar case in a biopsy of a female patient at Lenin Hospital, Holguin, Cuba it was many years back but even today I kept some slides for teaching.

Es un caso interesante y muy demostrativo, felicidades por las láminas histológicas. A propósito, yo tuve un caso similar en una biopsia de una paciente femenina en el Hospital Lenin de Holguin hace varios años y guardo aún algunas láminas para la docencia.

Nancy Ríos Hidalgo
Holguin. Cuba

- **yuseima govantes** (08/11/2005 20:20:02)

muy interesante el caso

- **Maribel DONASTORG** (10/11/2005 13:18:12)

Felcidades a los autores, se confunde con un sprue por los sintomas, no he tenido ningun caso .

Maribel Donastorg

Web mantenido y actualizado por el [Servicio de informática](#). Modificado: 31/01/2006 2:23:53